

Jorge Guadilla, Emilio Lopez-Vidriero,  
Rosa Lopez-Vidriero, Sabino Padilla,  
Diego Delgado, Rafael Arriaza, and Mikel Sanchez

---

### 10.1 Introduction

The lateral elbow pain has been named differently along the years.

Lateral epicondylitis was first described in the medical literature by Runge in 1873 [1].

The term “tennis elbow” appeared ten years later and remained since its initial description by Major who in 1883 described the “lawn tennis arm” [2].

Nevertheless, it is known that less than 10 % of patients consulting for this condition are actually tennis or racquet sport players [3].

Also called “lateral elbow pain” or “chronic lateral elbow pain,” this term is wide enough to include different clinical conditions. In the literature other names as “lateral epicondylalgia,” “shooter’s elbow,” or “archer’s elbow” can be found to describe conditions that have in common the lateral elbow pain [4].

The most used term is “lateral epicondylitis” and was previously considered to be a tendinitis, arising as inflammation of the tendon [5–7]. However, the current consensus is that microtrauma from excessive and repetitive use of the forearm extensors initiates a degenerative process with a paucity of inflammatory cells. Therefore, histologically it is said to be more a tendinosis (epicondylosis) than a tendinitis [8–10]. However, there is a last years’ trend that establishes that inflammation plays a role in general tendinopathy more than suspected. Thus, degeneration (osis) and inflammation (itis) could both be involved in the origin and progression of tendinopathies triggered by stressful stimuli such as mechanical stress present in the lateral epicondylitis [11, 12].

The condition which is going to be described along this chapter is an enthesopathy of the lateral epicondyle, and the most commonly affected muscle is the extensor carpi radialis brevis (ECRB) [13].

In the remainder of this chapter, the term lateral epicondylitis (LE) is going to be used.

---

### 10.2 Incidence and Related Sports

Tendon injuries, both acute and chronic (or tendinopathy), affect the quality of life, increase the costs of health care, and lead to stop sporting activities of a quite high amount of patients and sport professionals.

---

J. Guadilla • S. Padilla • D. Delgado • M. Sanchez  
Unidad de Cirugía Artroscópica, Vitoria, Spain

E. Lopez-Vidriero, MD, PhD (✉)  
Chief of Traumatology, Department at Ibermutuamur  
Sevilla, ISMEC. International Sports Medicine Clinic,  
Arjona 10. Bajo, Sevilla 41001, Spain  
e-mail: [director@ismec.es](mailto:director@ismec.es)

R. Lopez-Vidriero  
ISMEC. International Sports Medicine Clinic,  
Arjona 10. Bajo, Sevilla 41001, Spain

R. Arriaza  
Arriaza Asociados, La Coruña, Spain

The prevalence of lateral epicondylitis (LE) in the general population has been reported to be between 1 % and 3 % in adults, with no gender differences (es la misma referencia para todo el parrafo, la que aparece al final). This condition is most prevalent in the fifth decade of life, with peak incidence occurring between the ages of 45 and 60 years [14].

However, most publications are available about the incidence of LE. More comprehensive population-based studies are necessary [15].

Occupational risk factors, forceful activities, high force combined with high repetition or awkward posture, and the use of vibratory tools are associated with epicondylitis [16]. Any activity that involves overuse of the wrist extensor or supinator muscles may be the cause of this condition. The most commonly affected muscle is the ECRB [13, 17].

Epicondylitis is more common in the dominant elbow than in the nondominant, which means that exposure to physical load factors is involved in lateral epicondylitis [18, 19].

Despite the fact that less than 10 % of patients with this syndrome are actually tennis players, it is estimated that even more than 50 % of those who play tennis will experience some degree of lateral elbow pain along their lifetimes [20, 21]. In addition, the incidence of lateral epicondylitis is significantly higher in nonexpert than in expert tennis players [22] and those who use a one-handed backhand stroke [23].

The most common cause is overuse or repetitive strain caused by repeated extension or bending back of the wrist against resistance. Therefore, during the practice of tennis in case of a poor forehand or backhand technique, the wrist is bent when striking a backhand and huge forces are transferred through the tendons to the elbow rather than through the entire arm. Also, if the racquet grip is too small, the muscles work harder increasing the forces through the ECRB tendon. Strings that are too tight and playing with wet, heavy balls will transmit more shock and energy to the forearm.

Thus, some authors highlighted that racquet sports may cause the condition due to a combina-

tion of (1) incorrect technique, (2) extended duration of play, (3) frequency of play, (4) size of the racquet handle (affecting the lever arm of the force applied through the forearm), and (5) racquet weight [3, 23, 24].

Lateral epicondylitis is common in athletes of all ages and skill levels due to increasing participation in sports involving overhead arm motions. Sports as mentioned tennis, windsurfing, rock climbing, javelin throwing, team handball, and wheelchair modalities have been involved in lateral epicondylitis and other elbow injuries [25].

---

### 10.3 Degenerative Tendinopathies

#### 10.3.1 Basic Science on Tendinopathies [26]

The basic components of adult tendon are water, collagen and elastic fibers, and cells (fibroblasts or tenocytes) organized in a tissue of mesenchymal origin. The cell component mainly consists in fibroblasts (tenocytes; 95 %), with synovial and endothelial cells and chondrocytes, making up less than 5 % of the total volume. Tenocytes are responsible for generating and maintaining the extracellular matrix (ECM), with the functionality and viability of the former depending on the quality of the ECM. The extracellular matrix contains 65–80 % of type I collagen and elastin fibers, which together make up 2 % of the dry weight of the tendon (it should be remembered that 50–70 % of a tendon is water). Other elements such as proteoglycans, glycosaminoglycans, various structural proteins such as integrins (which bind to laminin, fibronectin, and tenascin), and a group of enzymes known as matrix metalloproteases (MMPs, mainly collagenases such as MMP1), which play key roles in the maintenance and remodeling of the ECM, are also present.

The tendon presents *three specific characteristics* that are vital for understanding both the fragility and instability of the metabolic balance

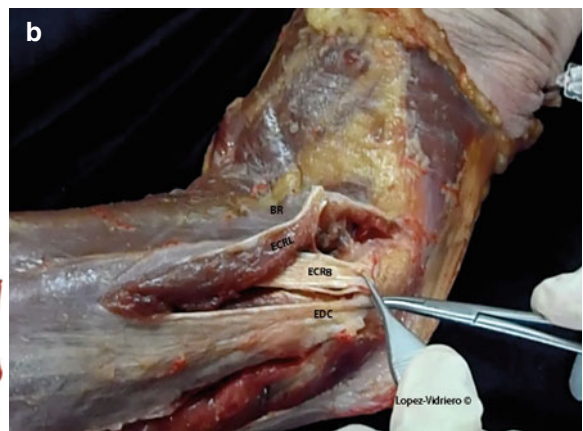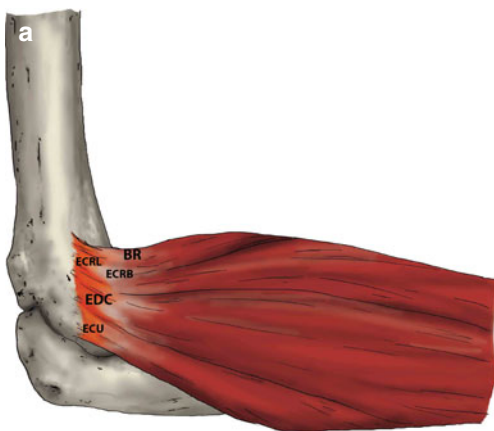
(remodeling/degradation) and its high mechanical strength.

1. Tendons act as an interface between the muscle and bone; thus they are the tissue transition zones. Mainly the myotendinous junction (MTJ) is subjected to high mechanical stresses. At the same time, the so-called osteotendinous junction (OTJ) also has its own structural and functional properties, which differ from those of the myotendinous junction but are also in a delicate metabolic balance.
2. During rapid growth periods and in early stages of the growth process, both tenoblasts and tenocytes exhibit high aerobic metabolic activity. Once they reach maturity, aerobic metabolism decreases and its anaerobic counterpart predominates.
3. There is a marked asymmetry between the limited number of tenocytes in the tendinous tissue and the large volume of extracellular matrix (ECM). In the adult or mature tendon, this cell/ECM ratio is even lower. Furthermore, this imbalance is amplified by the poor vascularity of the tendinous tissue.

These aspects mean that the tendon, together with the joint cartilage, is one of the structures

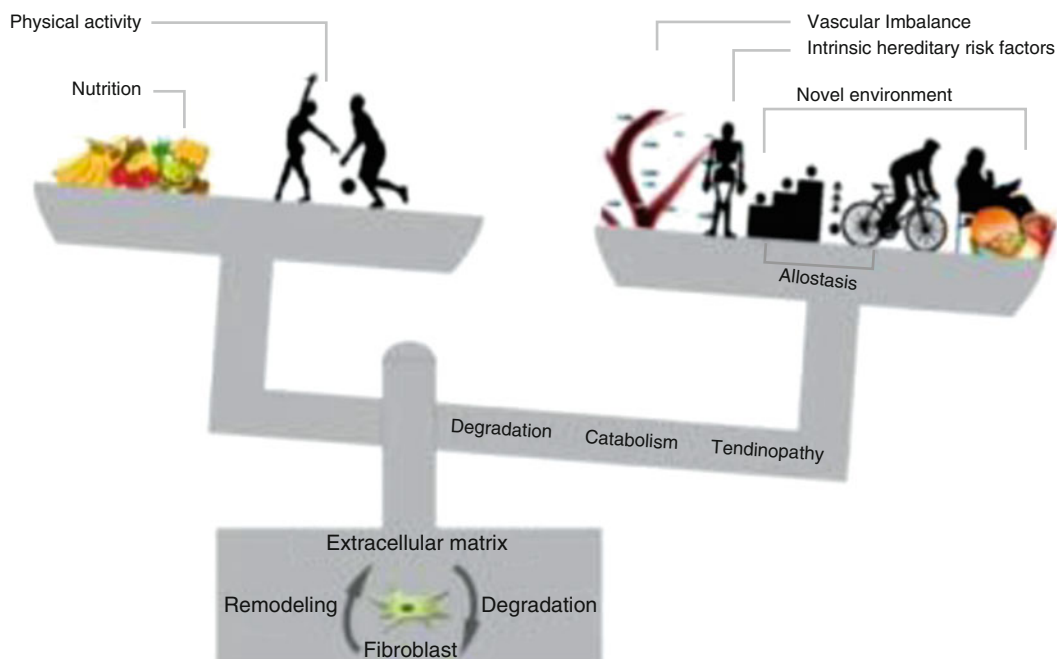
in the musculoskeletal system that must bear some of the highest mechanical stresses, which are amplified enormously during sporting activity, above all in elite sports, with their endless hours of repetitions and training. It is known that these highly specialized nature tissues pay a price for this specialization in terms of limited ability to repair themselves in the event of rupture, with low metabolic, vascular, nerve resources (Fig. 10.1).

The tendinous degeneration commonly referred to as tendinosis appears to be the end result of the inability of tenocytes (fibroblasts) to maintain the extracellular matrix in physiological conditions, mainly due to disruption of the remodeling/degradation (anabolism/catabolism) balance. This alteration of the extracellular matrix also affects the metabolism and fibroblast activity, thus perpetuating a vicious circle. There have been major immunohistochemical advances and gene expression analysis of pathological tendons showing proinflammatory mediators such as interleukin-1 $\alpha$ , interleukin- $\beta$ , TNF- $\alpha$ , as well as immunocompetent cells that may contribute to tendon inflammation [27]. In addition, extracellular matrix fragments stemmed from the breakdown of tenascin and hyaluronan may act as triggers of tendon resident macrophages, thereby unleashing an inflammatory response [27].



**Fig. 10.1** (a) Schematic drawing showing the extensor-supinator muscles. BR: Brachioradialis. ECRL: extensor carpi radialis longus. ECRB: extensor carpi radialis brevis (responsible for most of

the pathology). ECD: extensor digiti comunis. ECU: extensor carpi ulnaris. (b) Anatomic specimen showing dissection of the tendons. Notice the deeper location of the ECRB to the ECRL on the surface



**Fig.10.2** Tendinopathy fysiopathology theory. “With permission of authors of *A new biological Approach to Orthopedic Surgery and Sport Medicine 1st Ed. Teamwork Media*”

These intrinsic and extrinsic factors may determine the workload threshold beyond which the metabolic remodeling ability of tenocytes (fibroblasts) is insufficient to maintain an extracellular matrix. That can adapt to the higher level of mechanical stress resulting from the activity undertaken (allostasis). The most important factors that affect the disruption of the balance are shown in Fig. 10.2.

A number of pathophysiological hypotheses have been proposed to explain the underlying causal mechanism of tendinopathies. Thus, apoptosis, vascular changes, and pain-related inflammation have all been suggested by [28], whereas Alfredson and coworkers [29, 30] have described intratendinous lactate and glutamate alterations, as well as neovascularization phenomena. Thus, suggesting their metabolic/vascular/neural involvement in tendon degeneration, these mechanisms may interact in an overlapping manner (uncompensated vascularization, localized temperature increase, acidosis, new environment, and intrinsic factors).

### 10.3.2 Pathogenesis of Lateral Epicondylitis

In 1936, Cyriax [12] proposed that microscopic or macroscopic tears of the common extensor origin were involved in the pathogenesis of this condition. Thereafter, other investigators showed that the disease base is actually a degenerative tendinopathy [31–33] (añadir REFERENCIA).

The application of stress to a tendon normally leads to increased cross-linkage and collagen deposition [8]. When the rate of stretching and loads to the tendon exceed the tolerance of the tendon, a micro-tear results. Then the balance is lost, and the adaptation of the tendon to multiple micro-tears leads to tendinosis. Collagen within the tendons gets degraded because it is kept under high stress and it gets degraded in such quantity that the tenocytes are not able to replace it. From a mechanical point of view, these cumulative microtraumas result from repetitive wrist extension and alternating forearm supination and pronation [31, 32]. Histologically four

stages are described that result from such repetitive microtrauma [8, 34, 35]:

Stage 1: It starts with an acute inflammatory response, which can sometimes resolve completely.

Stage 2: If the aggression is maintained, a concentration of fibroblasts, vascular hyperplasia, and disorganized collagen, known in conjunction with angiofibroblastic hyperplasia, can be seen histologically.

Stage 3: Continuous accumulation of pathological changes leads to structural failure. In this stage the tendon suffers partial or complete rupture.

Stage 4: To the characteristics described in stage 2 or 3, other changes such as fibrosis are associated, as well as soft matrix calcification within the disorganized loose collagen and hard osseous calcification.

In 1973, Coonrad and Hooper were the first to describe macroscopic tearing in association with the histologic changes within the ECRB [31]. Six years later Nirschl called these histologic findings “angiofibroblastic hyperplasia” [33] as he showed that those findings were characterized by disorganized, immature collagen formation with immature fibroblastic and vascular elements. The term used today is angiofibroblastic tendinosis [36]. Ultrasonographically, tendon thickening or thinning, focal areas of hypoechogenicity, tendon tears, calcification, and even bony irregularity can be demonstrated mostly in the stages 3 and 4 [3, 37].

## 10.4 Diagnosis

Epicondylitis causes pain and disability, both in general population and in athletes. In addition, it has an economic cost in terms of days off the working activity and training. Thus, proper diagnosis and treatment are of paramount importance. An accurate, detailed, and thorough history and physical examination, combined with appropriate imaging studies in case of need, are

essential in understanding the mechanisms and pathophysiology of the injury and making a specific diagnosis [3, 33, 36].

### 10.4.1 History and Physical Examination

During the history it is advisable to ask the patient for those sporting activities or job circumstances that could cause or exacerbate the symptoms.

Clinically, LE is characterized by tenderness or pain over the lateral humeral epicondyle or, more typically, in the area where the common extensor muscles (specially the ECRB) meet the lateral humeral epicondyle. The patient may refer to a direct trauma to the lateral aspect of the elbow, but often the pain can be gradual and insidious. The pain often radiates down the forearm and unusually is proximal to the elbow. The intensity of the pain can range from intermittent and mild to constant and severe, affecting all daily activities.

The patient usually suffers weakness in grip strength that affects sports practice, working activities, and even activities of daily living as shaking hands, shaving, lifting, or raising a coffee mug.

It is recommended to rule out cervical spine pathology, followed by an examination of the entire upper extremity, with special attention to the shoulder, comparing with the unaffected, contralateral extremity. Palpation of the lateral humeral epicondyle or the origin of the ECRB will reproduce the pain.

A number of tests that could reproduce this pain, helping to the diagnosis, have been described:

- Resisted third finger extension can be painful because of selective recruitment of the ECRB tendon (Maudsley’s test)
- Resisted wrist extension with the elbow fully extended and in pronation stresses the whole common extensor origin and can reproduce the pain (Thompson maneuver).
- Asking the patient to lift a chair with the forearm pronated recreates the combination



**Fig. 10.3** Chair test or Gardner test

described above and also causes lateral elbow pain (“chair test” or Gardner test, Fig. 10.3) [38–40].

- Others like Bowden test, Cozen’s test, and Mill’s test can be helpful.

Generally, range of motion at the wrist and elbow is not affected. Grip strength may be decreased as a result of pain.

#### 10.4.2 Imaging and Complementary Test

In most cases a diagnosis of lateral epicondylitis can be made clinically. The X-rays can be helpful in demonstrating calcifications in the soft tissue at or near the insertion of the ECRB (found in 25 % of the cases [41]). They are helpful to rule out other potential causes of pain (including loose bodies, osteoarthritis, and osteochondritis dissecans) (Figs. 10.4 and 10.5).

Ultrasound imaging can be useful by identifying structural changes in the affected tendons (thickening or thinning, tendon tears, calcification, bony irregularity, etc.). Doppler ultrasound is able to detect neovascularization.

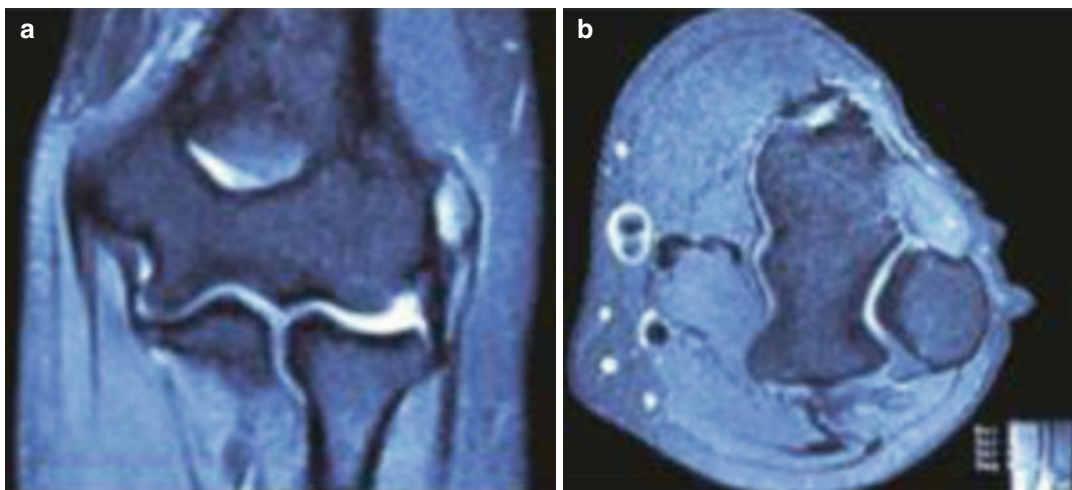
MRI can help to confirm diagnoses involving the extensor tendon origin. MRI has 90–100 % sensitivity and 83–100 % specificity for detecting epicondylitis [42]. Magnetic resonance imaging may also be useful if concomitant intra-articular pathology or ligamentous injuries are suspected.

Electromyography can be useful in excluding posterior interosseous nerve entrapment (radial tunnel syndrome).

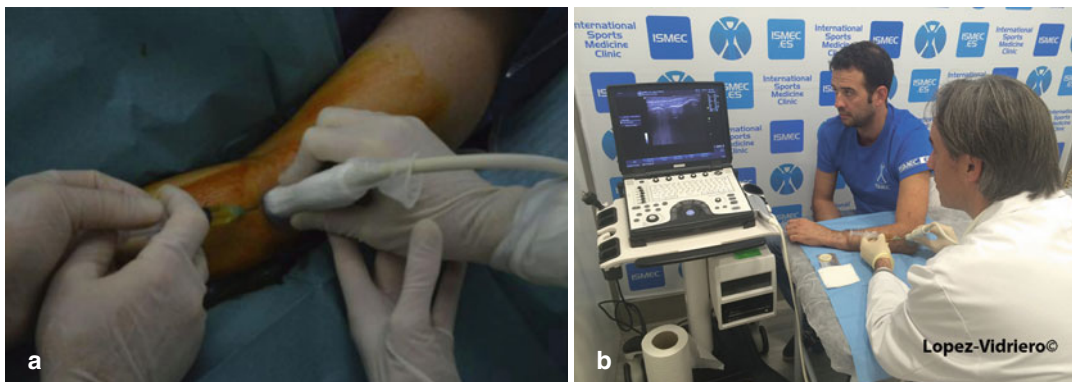
#### 10.4.3 Differential Diagnosis

Accurate diagnosis of lateral epicondylitis may be difficult since there are other conditions with similar symptoms (pain and reduced strength).





**Fig. 10.4** MRI images of a lateral epicondylitis



**Fig. 10.5** (a) Ultrasound guided injection with 4 hands. The surgeon injects while is helped by the radiologist using the probe. (b) Ultrasound guided injection with 2 hands. The surgeon triangulates by himself injecting with one hand while the other holds the probe. The skin is pre-

pared with chlorhexidine. Notice that sterile gel is used. The probe is protected with sterile latex sheath. The needle in the screen generates the typical reverberance due to the fact that is made of metal

Differential diagnosis for lateral epicondylitis has to include [3, 24, 33, 36]:

1. Cervical radiculopathy with pain irradiated to elbow and forearm.
2. Elbow overuse due to an ipsilateral shoulder malfunction (compensatory mechanism).
3. Entrapment of the posterior interosseous nerve (PIN), also known as radial tunnel syndrome, which affects 5 % of LE patients, does not cause increased pain with resisted wrist extension (see Sect. 4.1). Pain may be caused by resisted forearm supination as the supinator muscle is one of the areas of compression of this nerve. Electromyography and local injection of anesthetic to the region of the PIN may relieve the pain [43].
4. Joint problems: Ulnar collateral ligament injury, loose bodies, degenerative changes at the radiocapitellar joint, and osteochondritis dissecans. Rajeev and Pooley found 59 % of degenerative changes in 117 elbow arthroscopies performed for LE treatment [44]. It should be taken into account for the treatment of LE either in young or in middle-aged population.

5. Infection or tumors around or within the joint may also mimic LE clinical features and sometimes could appear as a mass.

## 10.5 Treatment of Lateral Epicondylitis

The aims of treatment for LE should be:

- Pain control
- Preservation of movement-function of the joint and upper limb
- Improvement in grip strength and endurance
- Return to normal function and activity
- Avoidance of further histological and clinical deterioration

Some studies have reported unpredictable healing patterns and have identified factors linked to poor outcomes. In this way, high baseline pain scores, manual work, and involvement of the dominant extremity have directly seen related to worse outcomes [14].

### 10.5.1 Described Treatment Options

Some authors have shown that the lateral elbow tendinopathy is a self-limited condition, and rest with or even without the use of some analgesic or anti-inflammatory medication in the acute phase of pain could resolve the symptoms.

The average duration of a typical episode is about 6 months to 2 years, but most patients (89 %) recover within 1 year [45].

To date, a standardized, universally accepted program for LE treatment has not been established by the orthopedic surgeon's community [3]. It leads to a wide diversity of treatment ranging from an expectant waiting approach, nonsteroidal anti-inflammatory drugs (NSAIDs), physical therapies, bracing, acupuncture, laser therapy, extracorporeal shock wave therapy, percutaneous radiofrequency thermal lesioning, topical nitrates, injection of glucocorticoid, botulinum toxin, autologous blood injection, and platelet-rich plasma therapies to surgery.

The choice, as reported by some studies depends on experience, expertise, and equipment at any given clinic or center. What is quite clear is that patient education is usually one of the important core elements of any plan or protocol.

The evidence indicates that wait and see policy would be enough for most patients [45, 46]. Injection with glucocorticoids has been used since the 1950s and has been the treatment of choice for most of the physicians. However, nowadays its efficacy and utility are considered controversial, since some studies addressed that long-term outcome of steroid injections is poorer than expected and could even alter the ability to heal and damage the tendon and tissues around. It is reported that 72 % of patients treated with steroid injections experience a recurrence within 12 months, compared with 9 % in those treated with a wait and see strategy [47–49].

Furthermore, as confirmed by the systematic review by Dean et al. [50], the local administration of glucocorticoid has significant negative effects on tendon cells, including reduced cell viability, cell proliferation and collagen synthesis, collagen disorganization, and cell necrosis, leading to a reduction of mechanical properties of the tendon. This should mean that in case of planning an infiltration of glucocorticoids for any tendinopathy and the use of an ultrasound guidance would be of paramount importance to avoid intratendinous injection.

It is well established that surgery is reserved for patients who fail to respond to nonoperative treatments, and multiple variations on open approach as percutaneous and arthroscopic procedures have been described. Studies of Nirschl and Pettrone [33] are considering that a range of 4–11 % of patients ultimately could require surgical treatment for relief of their symptoms.

Until today, the evidence about surgical treatment for LE is lacking, and the Cochrane Library has classified surgical treatment as having insufficient evidence to support or refute its use [51]. Despite exhaustive nonsurgical management and even correct surgical intervention, there is a small percent of patients who continue to feel symptoms, usually in terms of pain. In such cases the possibility of a wrong initial diagnosis or an associated pathology should be considered and ruled out.



### 10.5.2 Biological Therapies for Tendinopathies: PRP

Despite the fact that there are many options to treat injured tendons, as described previously, it is a reality that none of those are foolproof and it leads to the need of further studies and investigations on pathogenesis of tendon damage to understand and develop new strategies of treatments.

Therefore, mainly in the last decade, minimally invasive interventions with the theoretical ability of boosting the healing response or neutralizing degenerative changes in tendinopathy have received the watchful eye of the community and are being investigated.

Among the emerging technologies, with “biologically friendly” or “regenerative” profile, autologous whole blood and platelet-rich plasma (PRP) have been recently used in several clinical studies for the treatment of LE. PRP is defined as “a sample of autologous blood with concentrations of platelets above baseline values” [52].

The management of musculoskeletal injuries with PRP therapies has been advocated since 2003 [53], when Sánchez et al. published, as far as we know, the first paper on the use of PRP to treat an articular osteochondral avulsion of the knee.

Since then, this promising and innovative technology has stimulated translational research and interest among both the scientific and medical communities and has widened PRP applications to several musculoskeletal problems [54–57].

In the other hand, the term “PRP” is wide enough to generate confusion. Due to the fact that different preparations, with unequal cell population and activation method, with different amount of platelets above peripheral blood baseline, and, even more, with a nonconsensual protocol of application, are being used and investigated under the name of PRP [54, 58–60], therefore, different attempts of classification have been described, and some authors [55, 59, 60] have proposed systems that try to classify PRP systems by activation mechanism, platelet number, and/or cell content. The absence of a validated classification system that identifies crucial differences between PRP formulations makes it diffi-

cult to compare studies, and it involves that, despite intensive research and huge number of publications in the last years, there is a gap in the basic knowledge necessary to establish the best PRP product for each clinical condition, as well as the guidelines for clinical applications [57].

There is some evidence to state that PRP formulations (number of platelets, presence of white blood cells (WBCs), balance between platelet secreted and plasma proteins, mechanism of plasma activation) and/or application procedures (i.e., number of doses, volume, activation, and injection procedures) could be linked to clinical effect [57, 61, 62]. In this way there are enough reasons to believe that the use of leukocyte-rich PRP (L-PRP) and leukocyte-depleted PRP (pure or P-PRP) should not be the same (L-PRP is more proinflammatory when injected in rabbits [63], it increases the levels of metalloproteases when assayed in tenocyte cultures [64], and it induced more transient postinjection swelling and pain when injected into the knee for treatment of knee osteoarthritis [65]). There are some trials performed with a combination of local anesthetics and PRP. An *in vitro* study by Carofino et al. concluded that the addition of either anesthetics or corticosteroids to PRP resulted in statistically significant decreases in tenocyte proliferation and cell viability [66].

Even more, there is no consensus about the frequency and number of PRP injections in chronic injuries. The majority of the studies have been performed with a single PRP application, but in our opinion a degenerative process could not be solved with just one intervention, and therefore, two or even three injections would be more efficient than a single PRP application, but, actually, this issue remains to be clarified [67].

Our group has been using from the beginning of our research a 100 % autologous PRP with a standardized composition and dosage (PRGF-Endoret, BTI, Vitoria-Spain). It contains a moderated platelet concentration (2- to 2.5-fold increase compared with peripheral blood) [57], obtained after a single spinning. One of the most relevant and controversial issues is the presence of WBCs in PRP. The first and most widely used classification would define the system we are using, as pure PRP (P-PRP) because it does not

contain WBCs [59] The PRGF-Endoret is classified as type 4-B (minimal WBCs, activated with calcium chloride, and platelet concentration below 5) as proposed by Mishra et al. for sports medicine classification [55]. Finally, PRGF would fit in the P2-x-Bb category (platelet count greater than baseline levels to 750,000 platelets/mL, exogenous activation with calcium chloride, with WBCs, and specifically neutrophils, below or equal to baseline levels) according to the PAW (platelets, activation, and WBCs) classification [60].

#### **10.5.2.1 The Scientific Rationale behind the Use of PRP Use on Tendinopathies and Lateral Epicondylitis**

PRP preparations include growth factors, cytokines, and morphogens contained in platelets, as well as fibrinogen and other plasmatic proteins in a biologically balanced aggregate, managed and delivered in a pharmacological manner [68]. This may account for two special features: the resolution of inflammation and avoidance of fibrosis. In addition to containing GFs, PRP provides the damaged tissue with a transient biological fibrin scaffold, which stems from the polymerization of fibrinogen, a pleiotropic blood protein that regulates coagulation, inflammation, and tissue regeneration. PRP tendon infiltrations are aimed at recruiting, activating, and mobilizing satellite cells and resident macrophages which contribute to repair processes by cell signaling soluble factors. Once the activated preparation rich in growth factors is injected, this liquid-to-gel transition 3D injectable scaffold allows a successful filling of the tissue gaps and defects. With a local and gradual activation and a homogeneous distribution through and interaction with the ECM of tissue, it is converted into a matrix-like viscous and malleable structure [69]. This fibrin scaffold formed “in situ” as a provisional extracellular matrix and containing binding sites for cell adhesion as well as proteins such as thrombospondin-1 (TSP-1), alpha-1-antitrypsin fibronectin, acute phase proteins, or proteins related to lipid metabolisms [70] serves as a highway for

mechanical energy to transit from the environment to the cell, thereby bridging cell-to-cell tissue transition, promoting multicellular assembly, providing mechanical support and plastic-elastic stiffness which has a drastic impact on fates of different cell types such as fibroblasts [71], and endowing tissues with a suitable mechanical and chemical microenvironment for biological restoration. In addition, fibrin matrix, by heparin-binding domains, may sequester growth factors such as PDGF, FGF, HGF, BDNF, and VEGF [72, 73] and gradually release them later, exerting a synergistic action on tissue repair.

Since this dynamic sponglike fibrin-matrix scaffold is autologous, bio-reabsorbable, biocompatible, and free of leukocytes and red cells, PRP scaffolds might be considered the best tailored among all the tissue engineering materials [74].

There is a great deal of evidence illustrating the anabolic effects of PRPs on tendon cells [75–78]. PRP stimulates the synthesis of several types of collagen and other oligomeric matrix proteins, resulting in a synthesis of extracellular matrix which is conducive to the tendon anabolism and homeostasis. The wide spectrum of cell response in vitro and in vivo in both tendon stem cell differentiation and tendon cell proliferation, together with a substantial expression of VEGF and HGF by tendon cells, thereby generating a balanced angiogenesis, constitutes the rationale for the application of activated liquid and fibrin scaffolds to the injured site of the tendon to prompt the repair events in one area that brings about a great deal of morbidity. The infiltration of activated liquid form of PRP to a tendon damaged area elicits a set of sequential remodeling events that might lead to the tendon healing. Although the TGF- $\beta$ 1 family drives fibrogenesis and potentially might stimulate the formation of scar tissue in the tendon, the fibrotic effect of TGF- $\beta$ 1 present in the PRP would be either modulated, counterbalanced, or even hindered by the presence and local production of VEGF and HGF, a potent antifibrotic and anti-inflammatory agent, as has been shown by our work on cells cultured on fibrin matrices [79].

### 10.5.2.2 What Does Evidence-Based Literature Say about PRP and Lateral Epicondylitis?

In the last decade and taking into account the promising role of PRP for LE established by Mishra et al. in 2006 [80], different research projects have been developed, comparing PRP to different classically accepted treatments for LE, as corticosteroids, local anesthetics, and autologous blood. To date, all controlled clinical trials in epicondylitis (nine) have been performed with L-PRP [80–88]. So far there are no direct comparisons between L-PRP and pure PRP. There are also two case series papers with 6 and 30 patients and a single injection.

#### PRP Versus Bupivacaine Injections

Mishra and Pavelko [80] were the first people performing a case-control study with PRP on patients ( $n=20$ ) in which nonsurgical treatment had failed. Fifteen patients were injected with PRP and the other five with bupivacaine, intending these to act as controls. They found a 60 % improvement in VAS in PRP arm at 8 weeks and a 93 % reduction in VAS and function at 24 months of follow-up.

This study opened a way of research on PRP effect for LE, but the real value of it is conditioned by the design itself. In 2014 Mishra et al. [87] published a multicenter randomized and controlled trial (RCT) on 230 patients (116 injected with PRP and 114 with bupivacaine) that had at least 3 months of symptoms and had failed conventional therapy. The injection site was blocked in both cases using 0.5 % bupivacaine with epinephrine, before injecting PRP. At 12 weeks no significant differences between PRP and bupivacaine were found. However, significant VAS improvement and also significant success rates ( $>25$  % reduction in pain score versus baseline) at 24 weeks were encountered in PRP group.

Both studies were performed with a single injection of unactivated L-PRP and without ultrasound guidance.

#### PRP Versus Corticosteroid Injections

There are four RCT that compared PRP versus corticosteroid injections. Peerbooms et al. pub-

lished positive results at 6 and 12 months [81]. In an extension of the former study, Gosens et al. [82] confirmed those results 24 months after treatment. One-hundred patients with symptoms for 6 months were randomly assigned in the PRP group or the corticosteroid group. The injections were performed in two steps. First, one of 1 mL of PRP or corticosteroids with 0.5 % bupivacaine with epinephrine and, second, the remaining PRP with corticosteroids. Twelve weeks after the procedure, the VAS and Disabilities of the Arm, Shoulder, and Hand (DASH) scores were better in PRP than in corticosteroid group. Moreover, at the sixth month, the difference was already statistically significant [81], and the effects kept stable over a 2-year follow-up time [82].

In contrast, there are two other studies that did not find significant differences at 6 weeks or 3 months after treatment. In the first, the blinding system was not specified, the number of patients was 30, it was conducted for only 6 weeks, and they used the VAS and DASH scores [85]. The second was double blinded, the number of patients was 60, and it was randomized to receive PRP, saline, or glucocorticoid. The validated score was the Patient-Rated Tennis Elbow Evaluation (PRTEE) [86].

Interestingly, Kohl et al. [86] found that a single injection with either PRP or glucocorticoid was not significantly superior to a saline injection.

The PRP used in all these trials was L-PRP. The type of activation was unactivated in three papers and unknown in one [85]. Lastly all of them only used a single injection. Of these four studies only in Krogh's study the injection was under ultrasound control.

#### PRP Versus Autologous Whole Blood (AWB)

Three RCT compared L-PRP with autologous blood injections for refractory lateral epicondylitis. Creaney et al. [83] conducted a RCT of 150 patients, 80 receiving monthly US-guided two injections of PRP and 70 patients injected with autologous blood in the same fashion. Improvement was seen in PRTEE score for both

arms of the study at 6 months, but it was not statistically different.

Thanasas et al. [84] divided 24 patients equally into two groups, one treated with a single 3-mL injection of AWB and a second one with 3 mL of L-PRP, both under ultrasound guidance. VAS scale and Liverpool Elbow Score were used for the evaluation. PRP group had a significantly greater improvement in VAS scores than AWB group only at 6 weeks. This significant difference was not seen at 3 and 6 month controls.

In 2014 Raeissadat et al. [88] randomized 40 patients with duration of symptoms more than 3 months and VAS score of a minimum of 5. Group 1 was treated with a single injection of 2 mL of L-PRP and Group 2 with 2 mL of autologous blood. Pain and functional improvements were assessed with VAS scale, modified Mayo Clinic performance index for the elbow, and pressure pain threshold at baseline and 4 and 8 weeks. No statistically significant difference was noted between groups, and they concluded that both treatments are effective to treat LE with a slight superiority of PRP in 8-week follow-up.

The use of injections of PRP to treat LE has been seen to have an excellent safety profile [80–88].

Currently four controlled trials (comparing PRP to lidocaine, AWB, dry needle tendon fenestration, saline injection, and no injection) are being conducted as registered in [clinicaltrials.gov](http://clinicaltrials.gov). So far, research comparing both L-PRP and P-PRP is lacking, and it should be the aim of the medical community in order to clarify if the presence of WBCs is beneficial for the tendon healing.

## Conclusions

Since we know that depending on the presence of leucocytes, the amount of platelets from the baseline, and the type of activation we can categorize different types of PRP, the results from the studies and clinical trials performed with one of the described PRP cannot be extended to the others.

Thus, we should tend to standardize not only the PRP type but also the number of injections, the use of ultrasound to ensure the site of injection, the method of injection itself, the rehabilitation protocols, and even the patient outcome measure scores for this pathology.

In conclusion, there is currently insufficient evidence to support the use of PRP therapy for treating LE, due to the fact that the results of the different studies are controversial, given the heterogeneity in formulations and application protocols.

Therefore more research and an effort in standardization of PRP preparation methods and their applications protocol are still needed to establish the real role of PRP in the conservative treatment of LE.

### 10.5.2.3 PRP Protocol for LE [57]

In our group's treatment protocol, a patient complaining of chronic (more than 3 months) lateral elbow pain with the diagnosis of lateral epicondylitis should be advised to avoid the cause of the injury and start an individualized program of rehabilitation. In case of acute pain, some analgesics could be added.

In those patients with no improvement of the pain and with a physical examination that excludes other causes of lateral pain, a treatment program and ultrasound-guided PRP injections (in a sterile fashion), not only of the injured area of the tendon but also of the healthy both side extremes of the tendon and within the elbow joint, will be offered. The basis to inject in the surrounding healthy tissue is to activate the mesenchymal cells that are located there. So they can differentiate into tenocytes and migrate to the degenerate site. This phenomenon is called chemotaxis.

First of all, an ultrasound exploration of the lateral elbow is conducted. Then, once the ultrasound probe has been longitudinally located along the injured tendon, we insert the needle from distal to proximal, in a parallel track to the collagen fascicles; PRP is injected (shortly after CaCl<sub>2</sub> addition) within the site of altered tendon substance using a 21-G needle attached to a Luer Lock syringe. The intention is to inject the maximum volume that can be confined within the area of degeneration, commonly between 3 and 5 mL (depending on the specific tendon and clinical case). Next, at some point during the extraction of the needle, additional PRP is delivered to the healthy tendon. We also inject plasma around the tendon between the tendon and the paratenon, and

finally, a smaller volume is delivered into the associated fat and another 2–3 mL into the elbow joint.

Cold therapy is applied for approximately 10 min after the PRP injection in order to control pain. Local anesthetic and corticoids should be avoided due to the fact that they inactivate the PRP products. After the injection, the patients are instructed to limit physical activities for 24 h and to use cold therapy two to three times during the day. Only pain killers are allowed. NSAIDs should be avoided because they may interact in the healing process (Table 10.1).

In general, we perform two or three PRP injections separated 1 week each on an outpatient basis.

These criteria are largely arbitrary and are based on our clinical experience. Moreover, because PRP therapies promote early healing, 1 week may be adequate for monitoring individual outcomes and making decisions about further plasma injections. Ultrasonographic monitoring and symptoms drive our clinical decision regarding whether to perform additional PRP injections.

We do not change rehabilitation protocols after the PRP injection, and these include eccentric strengthening exercises, which are always personalized to the patient's condition. The only change is that we tend to move into different rehabilitation phases sooner.

**Table 10.1** Suggested PRP injection protocol for LE

Sterile fashion
NO local anesthetics neither corticosteroids
US exploration and localization of painful area/tendon (longitudinal axis)
Outpatient basis ultrasound guided: 2–3 PRP injection (3–5 mL), weekly reevaluation
Standard physical therapy protocol (eccentric exercises)

#### Pitfalls of Treatment

- In every sport-related injury, the balance between the rest needed for the treatment and the expectancy of sport practice is many times difficult to achieve.
- There are many types of PRP products, different protocols, and no consensus

about the way the PRP therapies should be applied for LE.

- The PRPs used in the clinical studies until date for this chronic and histologically degenerative condition have been L-PRP in the majority, applied a single time, without image control.
- The use of US-guided injection implies collaboration with the radiology department and expertise learned by the physician in charge of the patient.
- The use of local anesthesia or corticosteroids mixed with the PRP product may alter the effect of PRP.
- Despite advances in PRP science, there is a lack of level I studies to ensure that PRP therapies are definitively useful in LE.

#### Pearls of Treatment

The key to lateral epicondylitis treatment could be summarized as below:

- A good anamnesis and workup of the injured elbow.
- Any other cause of lateral elbow pain should be ruled out.
- Initially a “wait and see” policy with or without analgesic makes sense.
- Try to avoid injections of glucocorticoids, unless there is a huge inflammation component.
- Consider PRP therapies in chronic cases, always before surgical treatment.
- Perform the injections in a sterile fashion, under ultrasound control, without local anesthesia, and think about evaluating the patient the next week and repeating the injection depending on the sonographic findings, believing that a single injection is not enough for a degenerative tissue to heal.



### Clinical Case

Borja is a 31-year-old paddle tennis player. He is a former Spanish National Team member and actually playing in the Professional Tour. He is left handed. He came to our clinic complaining of progressive lateral elbow pain that limited his performance, and that was only temporary relieved by physiotherapy and one corticoid injection. Physical examination showed pain on palpation and resisted contraction of ECR muscles, without signs of tendon rupture in the US scan. A thorough review of the possible



causes of the pain onset revealed that his sponsors had changed his racquet design for the new season, and he had been playing with the new one for some two months before symptoms arose. After discussing the treatment options with the patient, we decided that he should return to his previous racket model (although it represented a minor problem with his sponsors, we solved by painting the old model with the new one's decoration), and that an orthobiological treatment would be better than more corticoid injections. Leukocyte-poor PRP (Mishra's type 4-B) was injected following our standard protocol for epicondylitis: under ultrasound control, only the growth-rich fraction (3 cc) was used, injecting it into the ECRB tendon origin, and also in the surrounding tissue; no local anesthesia was used, and the elbow was kept in a sling for the next 48 h. After the injection pain resolved, he was allowed to gradually return to training. One month later, he played his first competition match without pain, and symptoms have not recurred.

### References

- Runge F. Zur Genese und Behandlung des schreibes Kranfes. *Bed Klin Worchenschr.* 1873;10:245–8 (in German).
- Major HP. Lawn-tennis elbow. *BMJ.* 1883;2:557. letter.
- Luk J, Tsang R, Leung HB. Lateral epicondylalgia: midlife crisis of a tendón. *Hong Kong Med J.* 2014;20:145–51.
- Nirschl RP. Tennis elbow. *Orthop Clin North Am.* 1973;4:787–800.
- Nirschl RP. Elbow tendinosis/tennis elbow. *Clin Sports Med.* 1992;11:851–70.
- Bishai SK, Plancher KD. The basic science of lateral epicondylitis: update for the future. *Technol Orthop.* 2006;21:250–5.
- Kannus P, Józsa L. Histopathological changes preceding spontaneous rupture of a tendon: a controlled study of 891 patients. *J Bone Joint Surg Am.* 1991;73-A:1507–25.
- Kraushaar BS, Nirschl RP. Tendinosis of the elbow (tennis elbow). Clinical features and findings of histological, immunohistochemical, and electron microscopy studies. *J Bone Joint Surg Am.* 1999;81:259–78.
- Baker CL, Nirschl RP. Lateral tendon injury: open and arthroscopic treatment. In: Altchek DW, Andrews JR, editors. *The Athlete's elbow.* Philadelphia: Lippincott Williams & Wilkins; 2001. p. 91–103.
- Schulze-Tanzil G, Al-Sadi O, Wiegand E, Ertel W, Busch C, Kohl B, Pufe T. The role of pro-inflammatory and immunoregulatory cytokines in tendon healing and rupture: new insights. *Scand J Med Sci Sports.* 2011;21(3):337–51.
- Rees JD, et al. Tendons – time to revisit inflammation. *Br J Sports Med.* 2014;48:1553–7.
- Cyriax JH. The pathology and treatment of tennis elbow. *J Bone Joint Surg.* 1936;18:921–40.
- Walker-Bone K, Palmer KT, Reading I, Coggon D, Cooper C. Prevalence and impact of musculoskeletal disorders of the upper limb in the general population. *Arthritis Rheum.* 2004;51:642–51.
- Sanders TL et al. The epidemiology and health care burden of tennis elbow. A population-based study. *Am J Sports Med.* 2015; pii: 0363546514568087. [Epub ahead of print].
- Shiri R, Viikari-Juntura E. Lateral and medial epicondylitis: role of occupational factors. *Best Pract Res Clin Rheumatol.* 2011;25:43–57.
- Shiri R, Viikari-Juntura E, Varonen H, et al. Prevalence and determinants of lateral and medial epicondylitis: a population study. *Am J Epidemiol.* 2006;164:1065–74.
- Shiri R, Varonen H, Heliövaara M, Viikari-Juntura E. Hand dominance in upper extremity musculoskeletal disorders. *J Rheumatol.* 2007;34(5):1076–82.
- Hamilton PG. The prevalence of humeral epicondylitis: a survey in general practice. *J R Coll Gen Pract.* 1986;36(291):464–5.
- Boyer MI, Hastings II H. Lateral tennis elbow: "Is there any science out there?". *J Shoulder Elbow Surg.* 1999;8:481–91.

20. Priest JD, Braden V, Gerberich JG. The elbow and tennis. Part 1. *Phys Sports Med.* 1980;8:80.
21. Fichez O. Epicondylite: histoire naturelle et étude critique des différents traitements. *J Traumatol Sport.* 1998;15(3):163–72.
22. De Smedt T, de Jong A, Leemput WV, et al. Lateral epicondylitis in tennis: update on aetiology, biomechanics, and treatment. *Br J Sports Med.* 2007;41:816–9.
23. Eygendaal D, Rahussen FTG, Diercks RL. Biomechanics of the elbow joint in tennis players and relation to pathology. *Br J Sports Med.* 2007;41:820–3.
24. Tosti R, Jennings J, Sowards JM. Lateral epicondylitis of the elbow. *Am J Med.* 2013;126(357):357. e1-357.e6.
25. Hume PA, Reid D, Edwards T. Epicondylar injury in sport. Epidemiology, type, mechanisms, assessment, management and prevention. *Sports Med.* 2006;36(2):151–70.
26. Sánchez M, Anitua E. A new biological approach to orthopedic surgery and sports medicine. 1st ed. Vitoria: Team Work Media; 2013. Chapter 144–58.
27. Behzad H, Sharma A, Mousavizadeh R, et al. Mast cells exert pro-inflammatory effects of relevance to the pathophysiology of tendinopathy. *Arthritis Res Ther.* 2013;15(6):R184.
28. Sharma P, Maffulli N. Tendon injury and tendinopathy: healing and repair. *J Bone Joint Surg Am.* 2005;87:187–202.
29. Alfredson H, Bjur D, Thorsen K, Lorentzon R, Sandstrom P. High intratendinous lactate levels in painful chronic Achilles tendinosis. An investigation using microdialysis technique. *J Orthop Res.* 2002;20:934–8.
30. Alfredson H, Ohberg L. Sclerosing injections to areas of neo-vascularisation reduce pain in chronic Achilles tendinopathy: a double blind randomised controlled trial. *Knee Surg Sports Traumatol Arthrosc.* 2005;13:338–44.
31. Goldie I. Epicondylitis lateralis humeri (epicondylalgia or tennis elbow). A pathogenetical study. *Acta Chir Scand Suppl.* 1964;57 suppl 339:1.
32. Coonrad RW, Hooper WR. Tennis elbow: its courses, natural history, conservative and surgical management. *J Bone Joint Surg Am.* 1973;55:1177–82.
33. Ahmad Z. Lateral epicondylitis. A review of pathology and management. *Bone Joint J.* 2013;95-B:1158–64.
34. Chen J, Wang A, Xu J, et al. In chronic lateral epicondylitis, apoptosis and autophagic cell death occur in the extensor carpi radialis brevis tendon. *J Shoulder Elbow Surg.* 2010;19:355–62.
35. Nirschl RP, Pettrone FA. Tennis elbow. The surgical treatment of lateral epicondylitis. *J Bone Joint Surg Am.* 1979;61(6A):832–9.
36. Brummel J, et al. Epicondylitis: lateral. *Sports Med Arthrosc Rev.* 2014;22:e1–6.
37. Connell D, Burke F, Coombes P, et al. Sonographic examination of lateral epicondylitis. *Am J Roentgenol.* 2001;176:777–82.
38. Van Hofwegen C, Baker 3rd CL, Baker Jr CL. Epicondylitis in the athlete's elbow. *Clin Sports Med.* 2010;29:577–97.
39. Buckup K. Clinical tests for the musculoskeletal system: examinations-sign-phenomena. 2nd ed. Stuttgart: Thieme; 2008. p. 129–33.
40. Gardner RC. Tennis elbow: diagnosis, pathology and treatment: nine severe cases treated by a new reconstructive operation. *Clin Orthop.* 1970;72:248–53.
41. Edelson G, Kunos CA, Vigder F, Obed E. Bony changes at the lateral epicondyle of possible significance in tennis elbow syndrome. *J Shoulder Elbow Surg.* 2001;10:158–63.
42. Miller TT, Shapiro MA, Schultz E, et al. Comparison of sonography and MRI for diagnosing epicondylitis. *J Clin Ultrasound.* 2002;30:193–202.
43. Naam NH, Nemani S. Radial tunnel syndrome. *Orthop Clin North Am.* 2012;43:529–36.
44. Rajeev A, Pooley J. Lateral compartment cartilage changes and lateral elbow pain. *Acta Orthop Belg.* 2009;75:37–40.
45. Smidt N, Lewis M, van der Windt DAWM, Hay EM, Bouter LM, Croft P. Lateral epicondylitis in general practice: course and prognostic indicators of outcome. *J Rheumatol.* 2006;33:2053–9.
46. Sayegh ET, Strauch RJ. Does nonsurgical treatment improve longitudinal outcomes of lateral epicondylitis over no treatment? A meta-analysis. *Clin Orthop Relat Res.* 2015;473:1093–107.
47. Bisset L, et al. Mobilisation with movement and exercise, corticosteroid injection, or wait and see for tennis elbow: randomised trial. *BMJ.* 2006. doi:10.1136/bmj.38961.584653.AE.
48. Coombes BK, et al. Effect of corticosteroid injection, physiotherapy, or both on clinical outcomes in patients with unilateral lateral epicondylalgia a randomized controlled trial. *JAMA.* 2013;309(5):461–9.
49. Mardani-Kivi M, Karimi-Mobarakeh M, Karimi A, et al. The effects of corticosteroid injection versus local anesthetic injection in the treatment of lateral epicondylitis: a randomized single-blinded clinical trial. *Arch Orthop Trauma Surg.* 2013;133:757–63.
50. Buchbinder R, Johnston RV, Barnsley L, Assendelft WJ, Bell SN, Smidt N. Surgery for lateral elbow pain. *Cochrane Database Syst Rev.* 2011;3:CD003525.
51. Hall MP, Band PA, Meislin RJ, Jazrawi LM, Cardone DA. Platelet-rich plasma: current concepts and application in sports medicine. *J Am Acad Orthop Surg.* 2009;17(10):602–8.
52. Sánchez M, Azofra F, Anitua E, et al. Plasma rich in growth factors to treat an articular cartilage avulsion: a case report. *Med Sci Sports Exerc.* 2003;35:1648–52.
53. Sánchez M, Anitua E, Orive G, et al. Platelet-rich therapies in the treatment of orthopaedic sport injuries. *Sports Med.* 2009;39:345–54.
54. Mishra A, Harmon K, Woodall Jr J, Vieira A. Sports medicine applications of platelet rich plasma. *Curr Pharm Biotechnol.* 2012;13(7):1185–95.
55. Hsu WK, Mishra A, Rodeo SR, et al. Platelet-rich plasma in orthopaedic applications: evidence-based recommendations for treatment. *J Am Acad Orthop Surg.* 2013;21(12):739–48.
56. Sánchez M, Albillos J, Angulo F, et al. Platelet-rich plasma in muscle and tendon healing. *Oper Technol Orthop.* 2012;22:16–24.
57. Dohan Ehrenfest DM, Rasmusson L, Albrektsson T. Classification of platelet concentrates: from pure platelet-rich plasma (P-PRP) to leucocyte- and platelet-rich fibrin (L-PRF). *Trends Biotechnol.* 2009;27:158–67.
58. DeLong JM, Russell RP, Mazzocca AD. Platelet-rich plasma: the PAW classification system. *Arthroscopy.* 2012;28(7):998–1009.

59. Mastrangelo AN, Vavken P, Fleming BC, et al. Reduced platelet concentration does not harm PRP effectiveness for ACL repair in a porcine in vivo model. *J Orthop Res*. 2011;29:1002–7.
60. Wiegierinck JJ, Reilingh ML, de Jonge MC, et al. Injection techniques of platelet-rich plasma into and around the Achilles tendon: a cadaveric study. *Am J Sports Med*. 2011;39:1681–168.
61. Dragoo JL, Braun HJ, Durham JL, et al. Comparison of the acute inflammatory response of two commercial platelet-rich plasma systems in healthy rabbit tendons. *Am J Sports Med*. 2012;40:1274–81.
62. Sundman EA, Cole BJ, Fortier LA. Growth factor and catabolic cytokine concentrations are influenced by the cellular composition of platelet-rich plasma. *Am J Sports Med*. 2011;39:2135–40.
63. Filardo G, Kon E, Pereira Ruiz MT, Vaccaro F, Guitaldi R, Di Martino A, Cenacchi A, Fornasari PM, Marcacci M. Platelet-rich plasma intra-articular injections for cartilage degeneration and osteoarthritis: single- versus double-spinning approach. *Knee Surg Sports Traumatol Arthrosc*. 2012;20:2082–91.
64. Carofino B, et al. Corticosteroids and local anesthetics decrease positive effects of platelet-rich plasma: an in vitro study on human tendon cells. *Arthroscopy*. 2012;28(5):711–9.
65. Martin JJ, et al. Platelet-rich plasma (PRP) in chronic epicondylitis: study protocol for a randomized controlled trial. *Trials*. 2013;14:410.
66. Anitua E, Alkhraisat MH, Orive G. Perspectives and challenges in regenerative medicine using plasma rich in growth factors. *J Control Release*. 2012;157:29–38.
67. Anitua E, Sanchez M, Orive G. Potential of endogenous regenerative technology for in situ regenerative medicine. *Adv Drug Deliv Rev*. 2010;62(7–8):741–52.
68. Nurden AT. Platelets, inflammation and tissue regeneration. *Thromb Haemost*. 2011;105(Suppl1):S13–33.
69. Discher DE, Mooney DJ, Zandstra PW. Growth factors, matrices, and forces combine and control stem cells. *Science*. 2009;324(5935):1673–7.
70. Martino MM, Briquez PS, Ranga A, et al. Heparin-binding domain of fibrin(ogen) binds growth factors and promotes tissue repair when incorporated within a synthetic matrix. *Proc Natl Acad Sci U S A*. 2013;110(12):4563–8.
71. Anitua E, Zalduendo M, Prado R, et al. Morphogen and pro-inflammatory cytokine release kinetics from PRGF-Endoret fibrin scaffolds: evaluation of the effect of leukocyte inclusion. *J Biomed Mater Res A*. 2015;103(3):1011–20.
72. Anitua E, Orive G. Endogenous regenerative technology using plasma- and platelet-derived growth factors. *J Control Release*. 2012;157(3):317–20.
73. Zhang J, Wang JHC. Platelet-rich plasma releasate promotes differentiation of tendon stem cells into active tenocytes. *Am J Sports Med*. 2010;38:2477–86.
74. Schnabel LV, Mohammed HO, Miller BJ, et al. Platelet rich plasma (PRP) enhances the anabolic gene expression pattern in flexor digitorum superficialis tendons. *J Orthop Res*. 2007;25:230–40.
75. Anitua E, Sanchez M, Zalduendo MM, et al. Fibroblastic response to treatment with different preparations rich in growth factors. *Cell Prolif*. 2009;41:162–70.
76. Anitua E, Sanchez M, De la Fuente M, et al. Plasma rich in growth factors (PRGF-Endoret) stimulates tendon and synovial fibroblasts migration and improves the biological properties of hyaluronic acid. *Knee Surg Sports Traumatol Arthrosc*. 2012;20:1657–65.
77. Anitua E, Sánchez M, Nurden AT, et al. Autologous fibrin matrices: a potential source of biological mediators that modulate tendon cell activities. *J Biomed Mater Res*. 2006;77:285–93.
78. Mishra A, Pavelko T. Treatment of chronic elbow tendinosis with buffered platelet rich plasma. *Am J Sports Med*. 2006;34:1774–8.
79. Peerbooms JC, Sluimer J, Bruijn DJ, Gosens T. Positive effect of an autologous platelet concentrate in lateral epicondylitis in a double-blind randomized controlled trial: Platelet-rich plasma versus corticosteroid injection with a 1-year follow-up. *Am J Sports Med*. 2010;38:255–62.
80. Gosens T, Peerbooms JC, van Laar W, den Ouden BL. Ongoing positive effect of platelet-rich plasma versus corticosteroid injection in lateral epicondylitis: a double-blind randomized controlled trial with 2-year follow-up. *Am J Sports Med*. 2011;39:1200–8.
81. Creaney L, Walla A, Curtis M, Connell D. Growth factor- based therapies provide additional benefit beyond physical therapy in resistant elbow tendinopathy: a prospective, double-blind, randomised trial of autologous blood injections versus platelet-rich plasma injections. *Br J Sports Med*. 2011;45:966–71.
82. Thanasis C, Papadimitriou G, Charalambidis C, Paraskevopoulos I, Papanikolaou A. Platelet- rich plasma versus autologous whole blood for the treatment of chronic lateral elbow epicondylitis: a randomized controlled clinical trial. *Am J Sports Med*. 2011;39:2130–4.
83. Omar Aziza S, Maha EI, Amal SA, Mahmoud S. Local injection of autologous platelet rich plasma and corticosteroid in treatment of lateral epicondylitis and plantar fasciitis: randomized clinical trial. *Egypt Rheumatol*. 2012;34:43–9.
84. Krogh TP, Fredberg U, Stengaard-Pedersen K, et al. Treatment of lateral epicondylitis with platelet-rich plasma, glucocorticoid, or saline: a randomized, double-blind, placebo-controlled trial. *Am J Sports Med*. 2013;41:625–35.
85. Mishra AK, Skrepnik NV, Edwards SG, et al. Efficacy of platelet-rich plasma for chronic tennis elbow: a double-blind, prospective, multicenter, randomized controlled trial of 230 patients. *Am J Sports Med*. 2014;42:463–71.
86. Raeissadat SA, Rayegani SM, Hassanabadi H, et al. Is platelet-rich plasma superior to whole blood in the management of chronic tennis elbow: one year randomized clinical trial. *BMC Sports Sci Med Rehabil*. 2014;6:12.
87. Chaudhury S, de La Lama M, Adler RS, et al. Platelet-rich plasma for the treatment of lateral epicondylitis: sonographic assessment of tendon morphology and vascularity (pilot study). *Skeletal Radiol*. 2013;42:91–7.
88. Hechtman KS, Uribe JW, Botto-vanDemden A, Kiebzak GM. Platelet-rich plasma injection reduces pain in patients with recalcitrant epicondylitis. *Orthopedics*. 2011;34:92.